ACI NSW Agency for Clinical Innovation

Emergency Care Institute NEW SOUTH WALES

C-spine Imaging in ED

A point of care guide to interpreting CTs, plain films and rationalising their use in ED

Dr Kirsty Short, ECI Advanced Trainee

ECI recommended neuroanatomy website

- http://headneckbrainspine.com/Neuroanatomy-modules.php

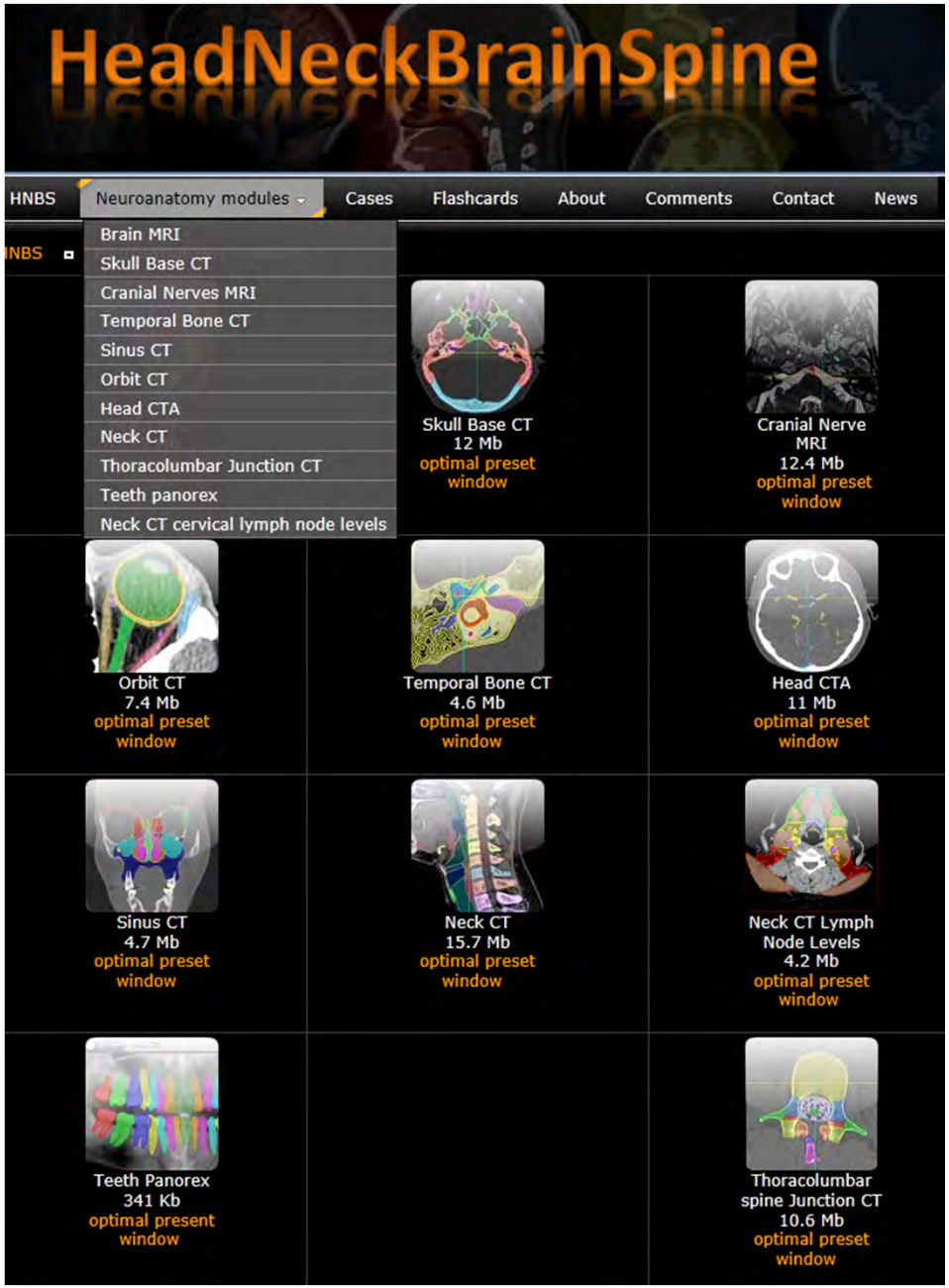

Who needs C-spine imaging?

- According to ***NEXUS*** Criteria radiography indicated *unless* following criteria met:
  - No posterior midline C-spine tenderness
  - No evidence of intoxication
  - A normal level of alertness
  - No focal neurologic deficit
  - No painful distracting injuries

Who needs C-spine imaging? (2)

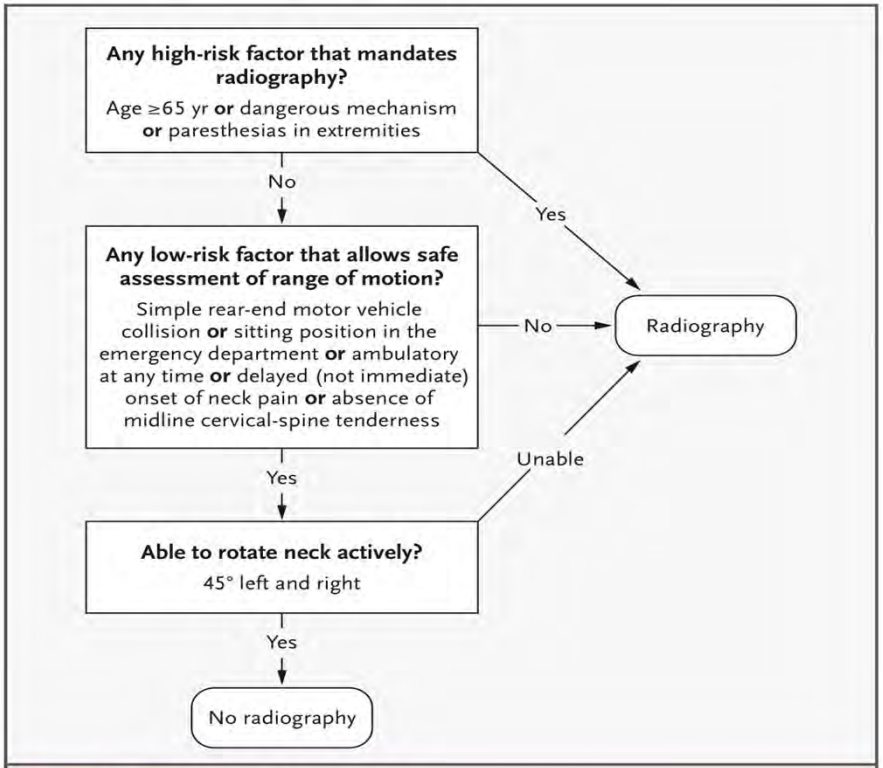

Figure 1. The Canadian C-Spine Rule.
For patients with trauma who are alert (as indicated by a score of 15 on the Glasgow Coma Scale) and in stable condition and in whom cervical-spine injury is a concern, the determination of risk factors guides the use of cervical-spine radiography. A dangerous mechanism is considered to be a fall from an elevation ≥3 ft or 5 stairs; an axial load to the head (e.g., diving); a motor vehicle collision at high speed (>100 km/hr) or with rollover or ejection; a collision involving a motorized recreational vehicle; or a bicycle collision. A simple rear-end motor vehicle collision excludes being pushed into oncoming traffic, being hit by a bus or a large truck, a rollover, and being hit by a high-speed vehicle.

CANADIAN C-SPINE RULE

- High-risk:
  - MVA >100km/hr
  - Fall >3ft/>5 steps
  - Axial compression injury
  - Focal neurology
  - (Predisposing medical condition)

CT or Plain Film?

- In reality CT commonly performed due to higher sensitivity, wide availability and speed of image acquisition

- CT recommended if:
  - High clinical suspicion of injury, even if normal X-ray
  - Inadequate plain film study
  - Suspicious plain film findings
  - Fracture seen on plain X-rays

- Lack of CT availability in rural NSW settings mean plain films often first line

ACEM Guideline

2.4 Possible cervical spine injury

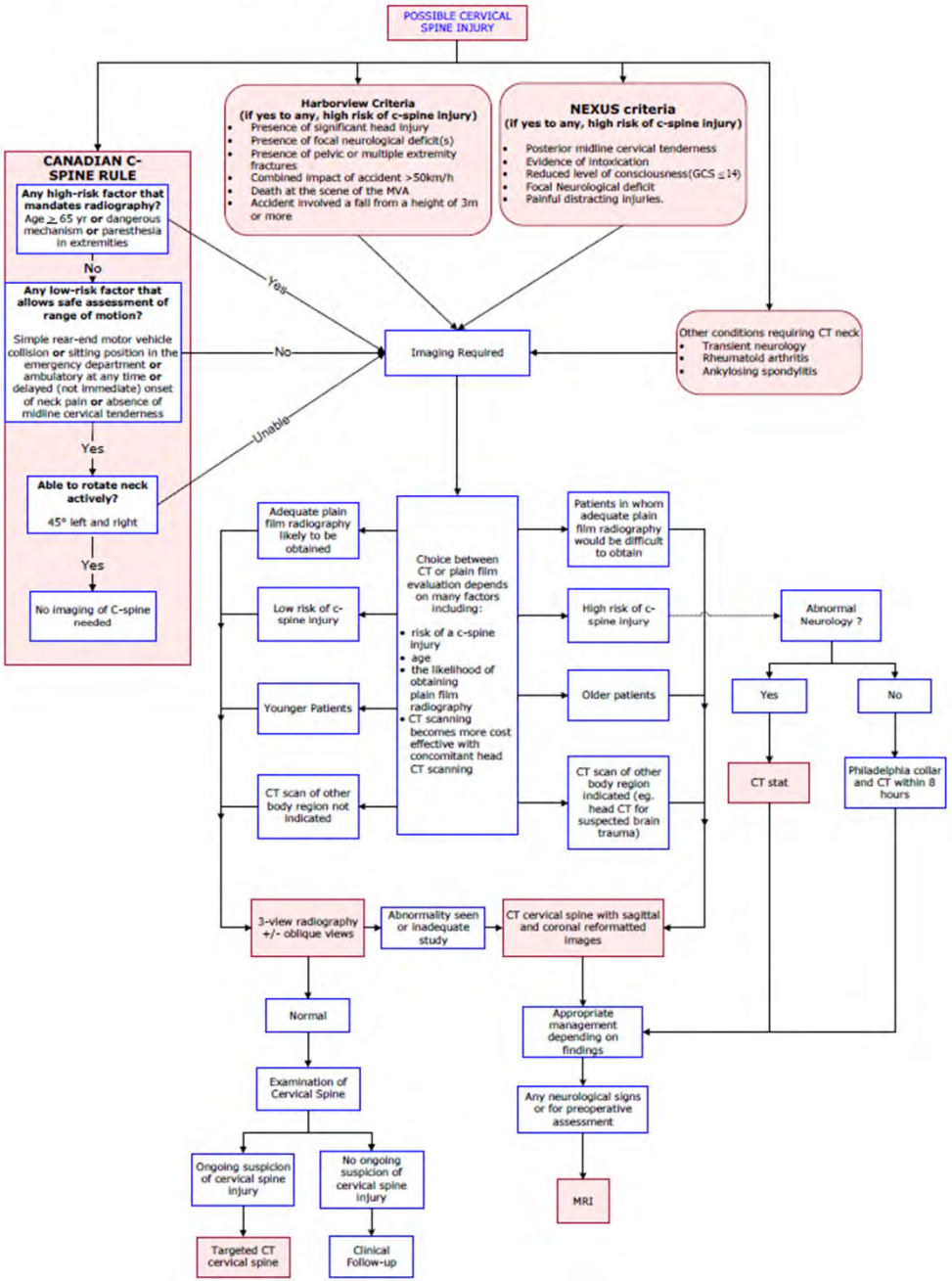

‘AABCDS’ of C spine Interpretation

Atlas

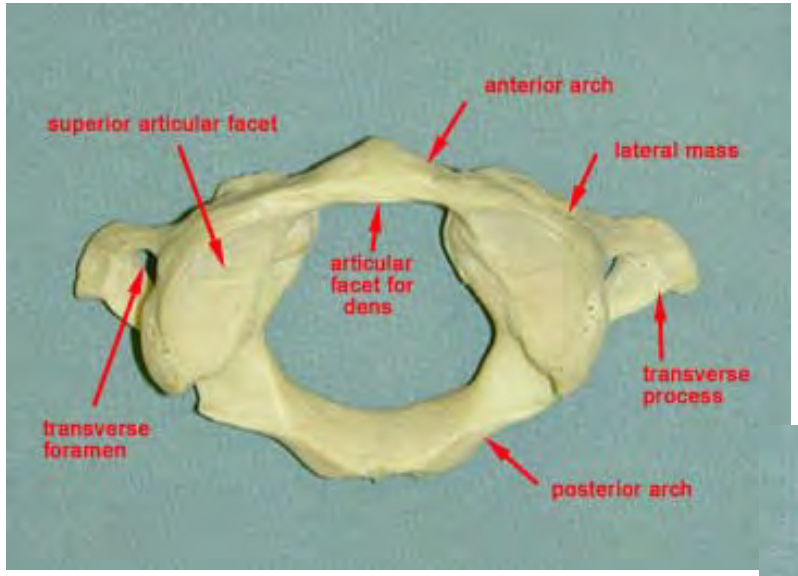
anterior arch
superior articular facet
lateral mass
articular facet for dens
transverse process
transverse foramen
posterior arch

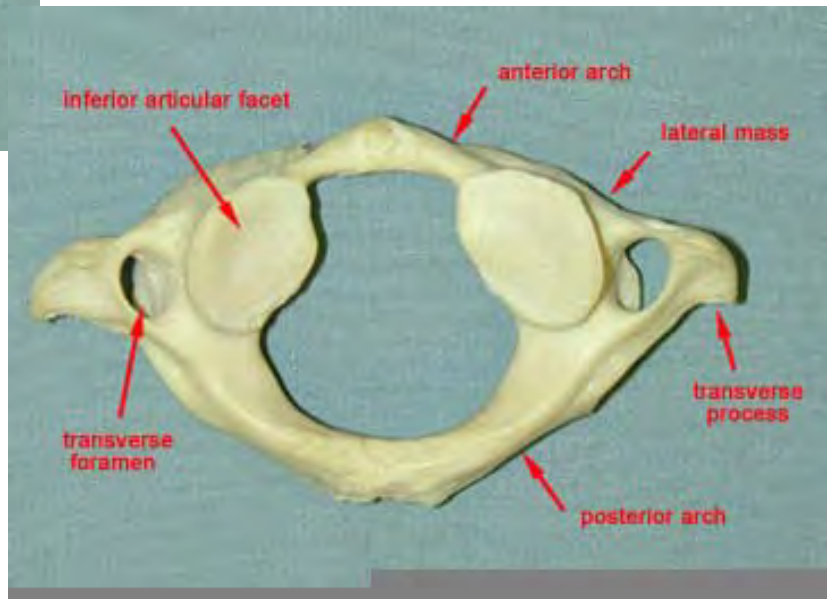
anterior arch
inferior articular facet
lateral mass
transverse process
transverse foramen
posterior arch

Axis

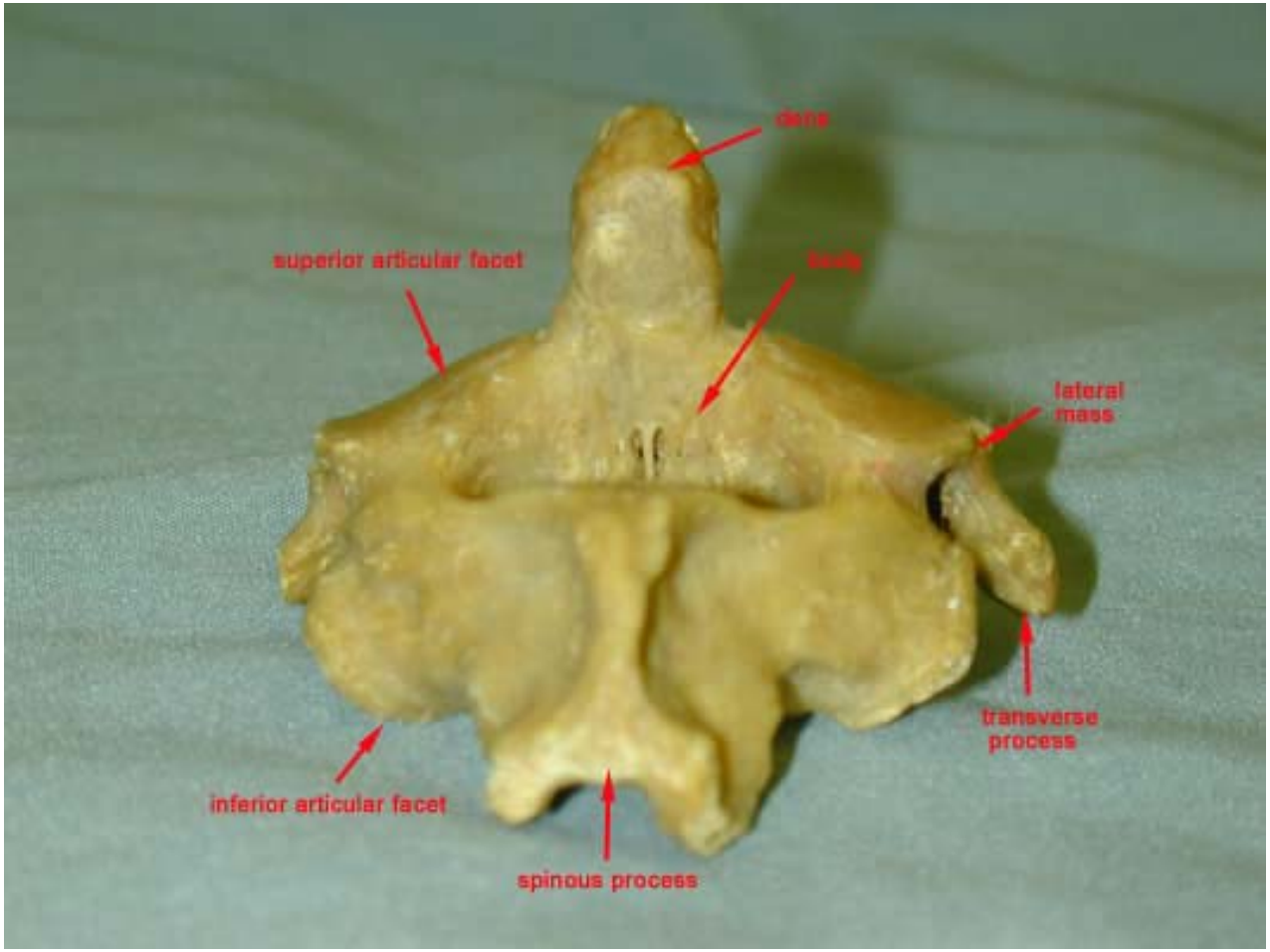
dens
superior articular facet
body
lateral mass
transverse process
inferior articular facet
spinous process

Articulation

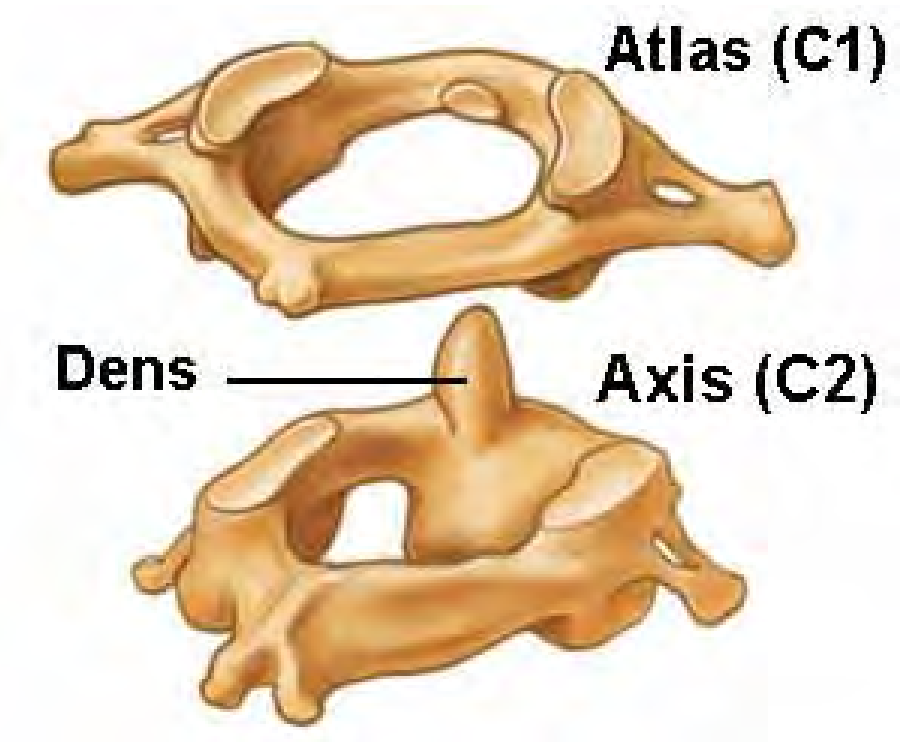

C4 – Typical vertebra

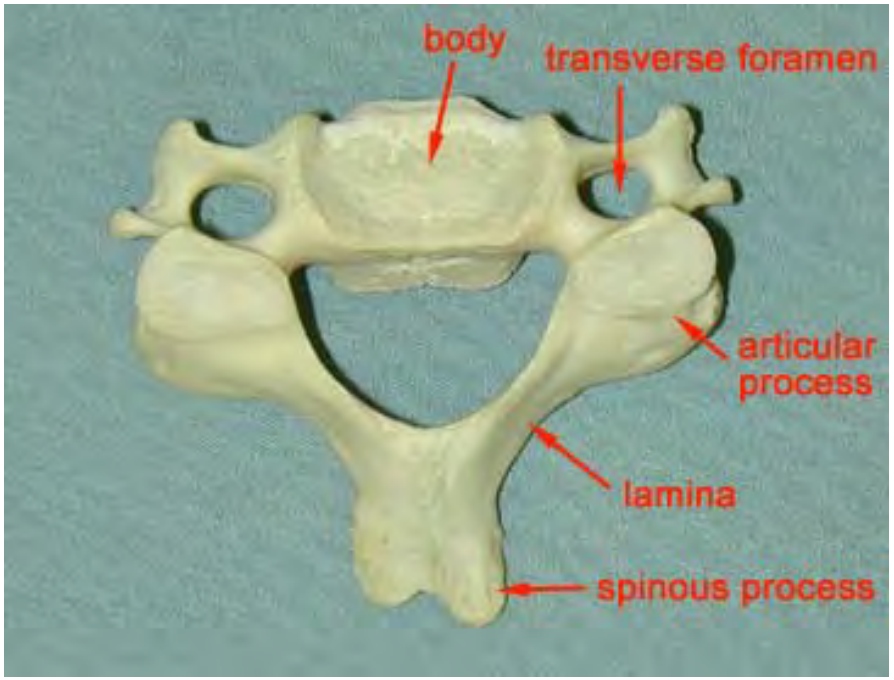

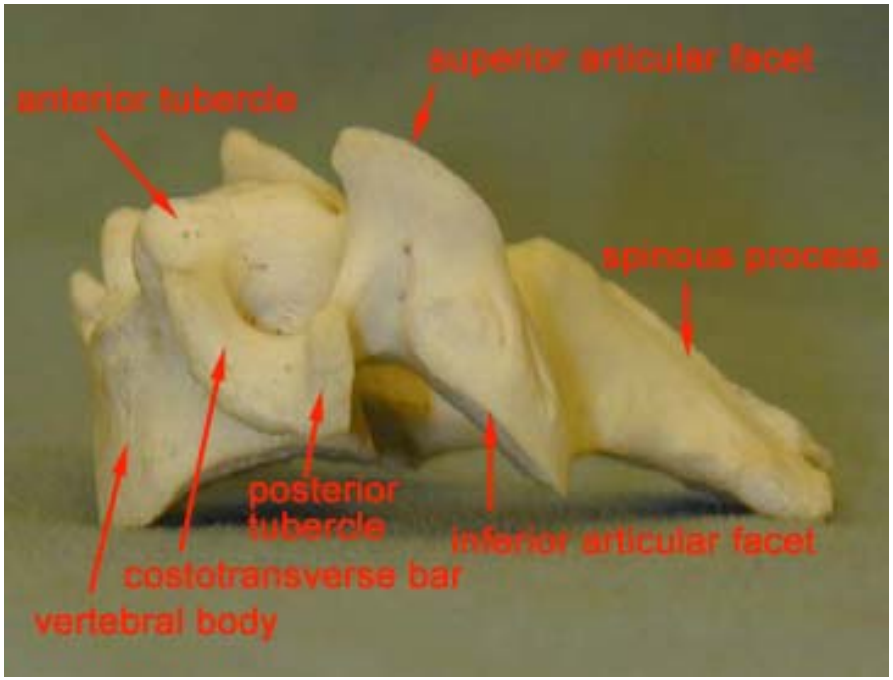

AABCDS Mnemonic

- **A =** Adequacy
- **A =** Alignment
- **B =** Bone
- **C =** Cartilage
- **D =** Disc
- **S =** Soft tissue

Plain film: Lateral/AP/odontoid views

CT: Axial, sagittal, coronal slices

Adequacy

All 7 vertebrae and C7-T1 junction

Alignment

- **Anterior vertebral line (1)**
  - Anterior margin of vertebral bodies (VBs)
- **Posterior vertebral line (2)**
  - Posterior margin of VBs
- **Spinolaminar line (3)**
  - Posterior margin of spinal canal
- **Posterior spinous line (4)**
  - Tips of spinous processes

Atlanto-occipital Alignment

- The anterior margin of the foramen magnum should line up with the dens
- The green line running downward from the dorsum sellae along the clivus and basion should point to the dens
- The posterior margin of

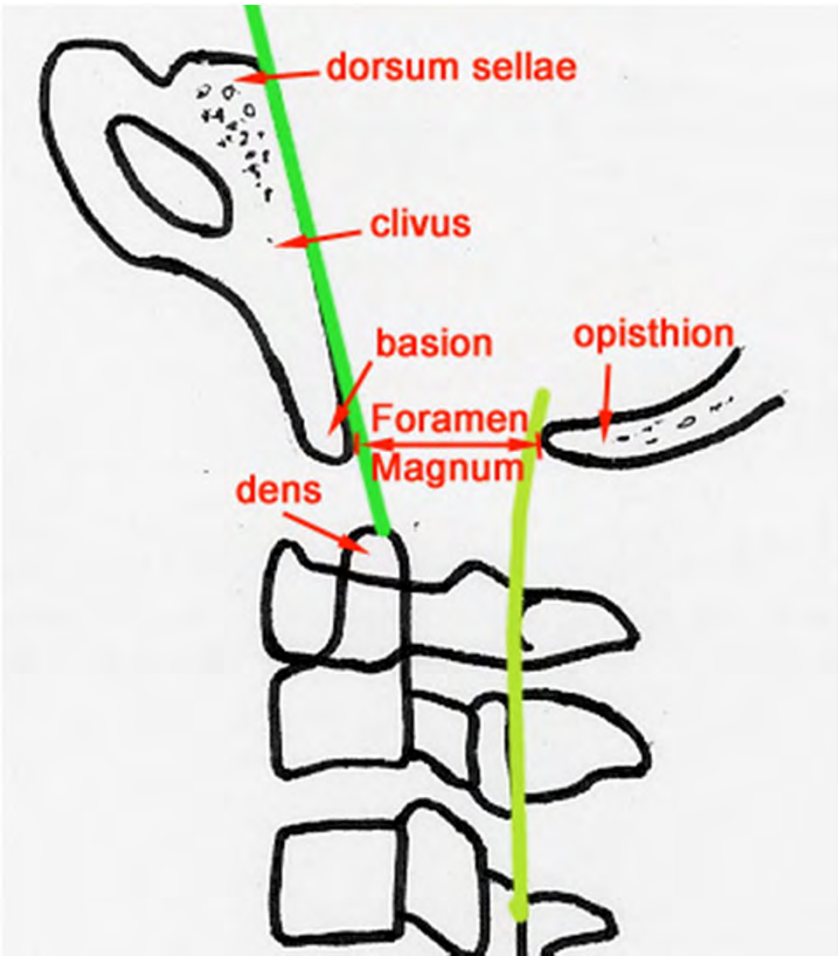

Atlanto-occipital Dislocation

- BC:AO = 0.6 to 1.0
- Ratio >1.0 = anterior cranio-cervical dislocation

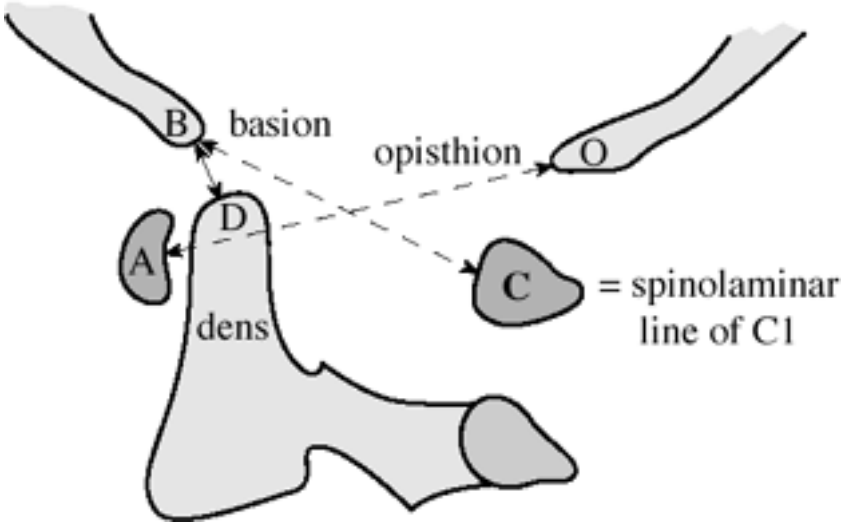

Bone: C1 & C2

Bone: C3-C7

- Trace the outline of each vertebrae
- The VBs should line up with a gentle arch (cervical lordosis)
- Bodies rectangular in shape and roughly equal in size
  - Height of C4/C5 may be slightly less than C3/C6
  - Ant height = post height

    (up to 3mm post difference allowed)

Bone

- **Pedicles**
- **Facet jts**
  - "Double cortical lines" due to slight obliquity from lateral projection
  - Joint space should be equal at all levels
- **Lamina**
- **Spinous processes**
  - Get progressively larger in the lower VBs

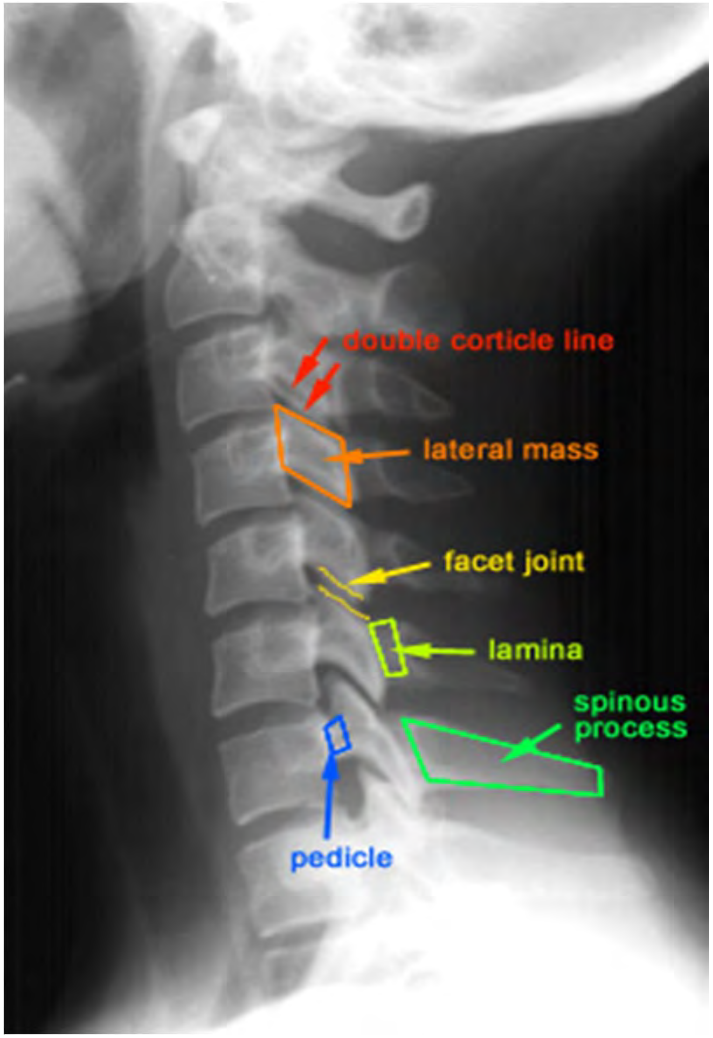

Cartilage

- Pre-dentate space < 3mm (adults), <5mm (kids)

Dens to C1 body

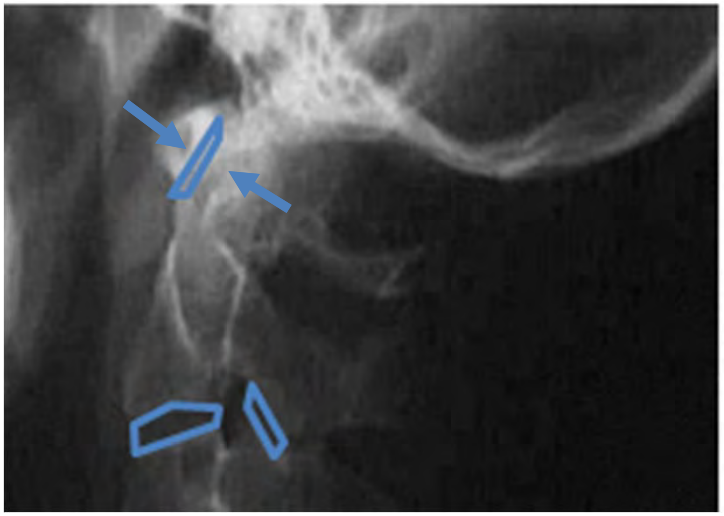

Disc Spaces

- Should be equal in height at A & P margins
- Symmetrical
- Approximately equal at all levels

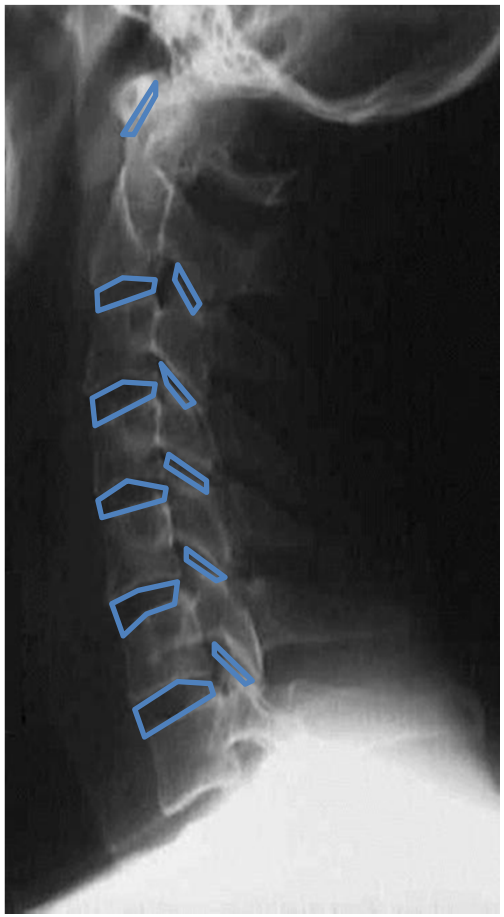

Soft Tissue Spaces

- High index of suspicion for underlying injury if enlarged
  - haemorrhage/occult fracture

Retropharyngeal space (C2-C4) - 5-7 mm

Retrotracheal space (C5-C7) - 22 mm

C1-C4 < ½ VB width, C4 onwards <1 VB width

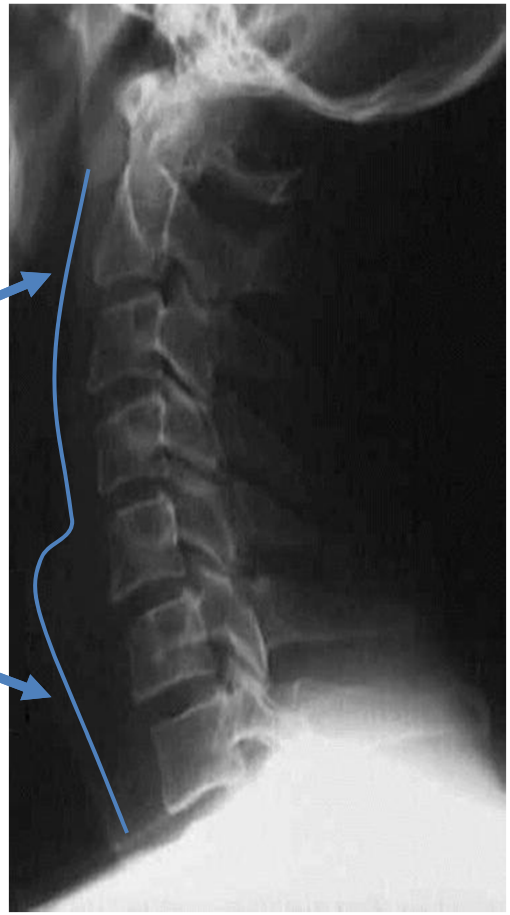

Type III Dens # on CT

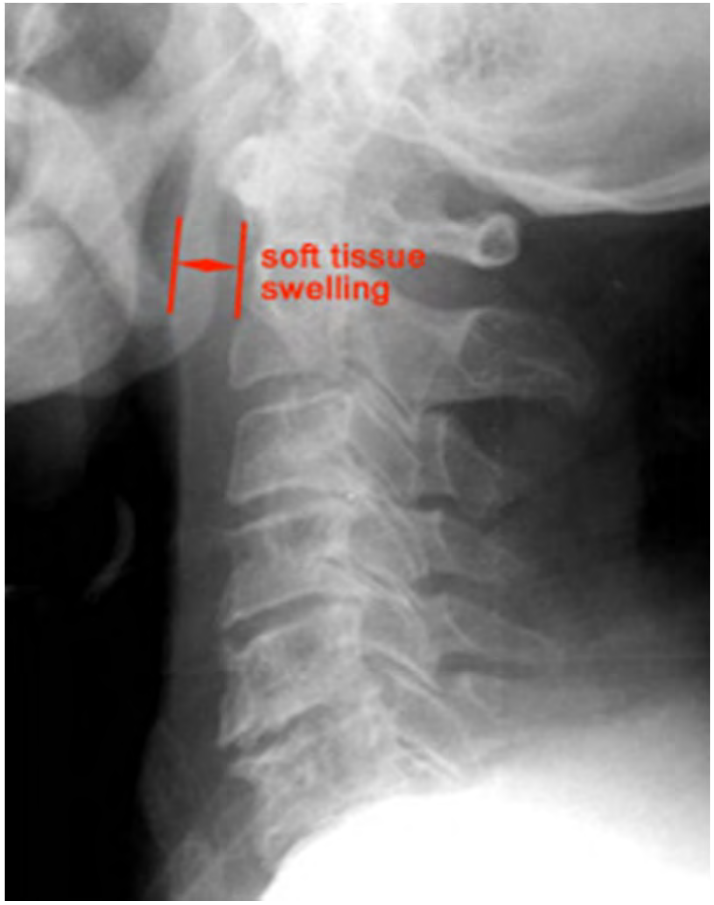

The AP view

- Assess alignment of edges of the VBs and articular pillars
- Equal height of VBs and jt spaces
- Spinous processes midline
  - Suspect a facet dislocation if displaced to one side

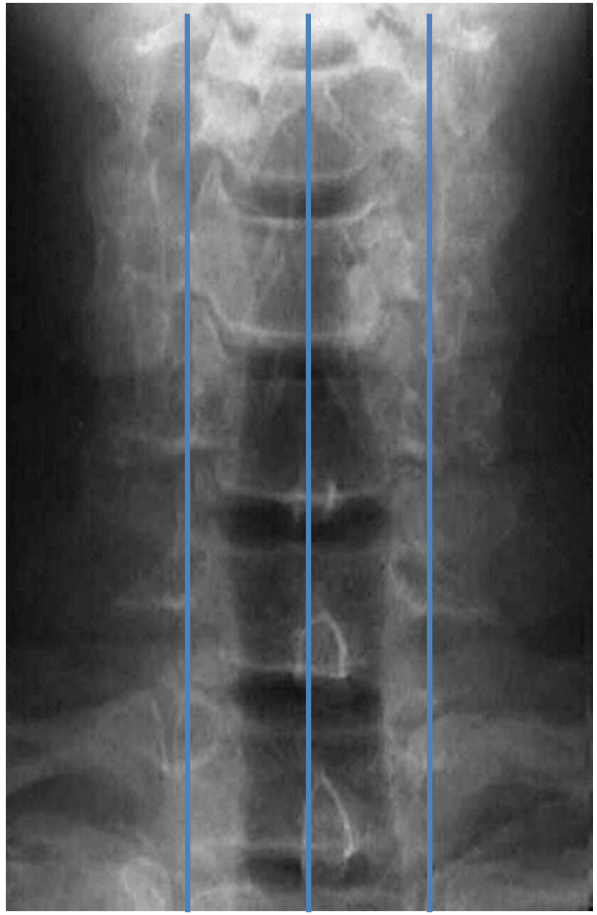

AP View

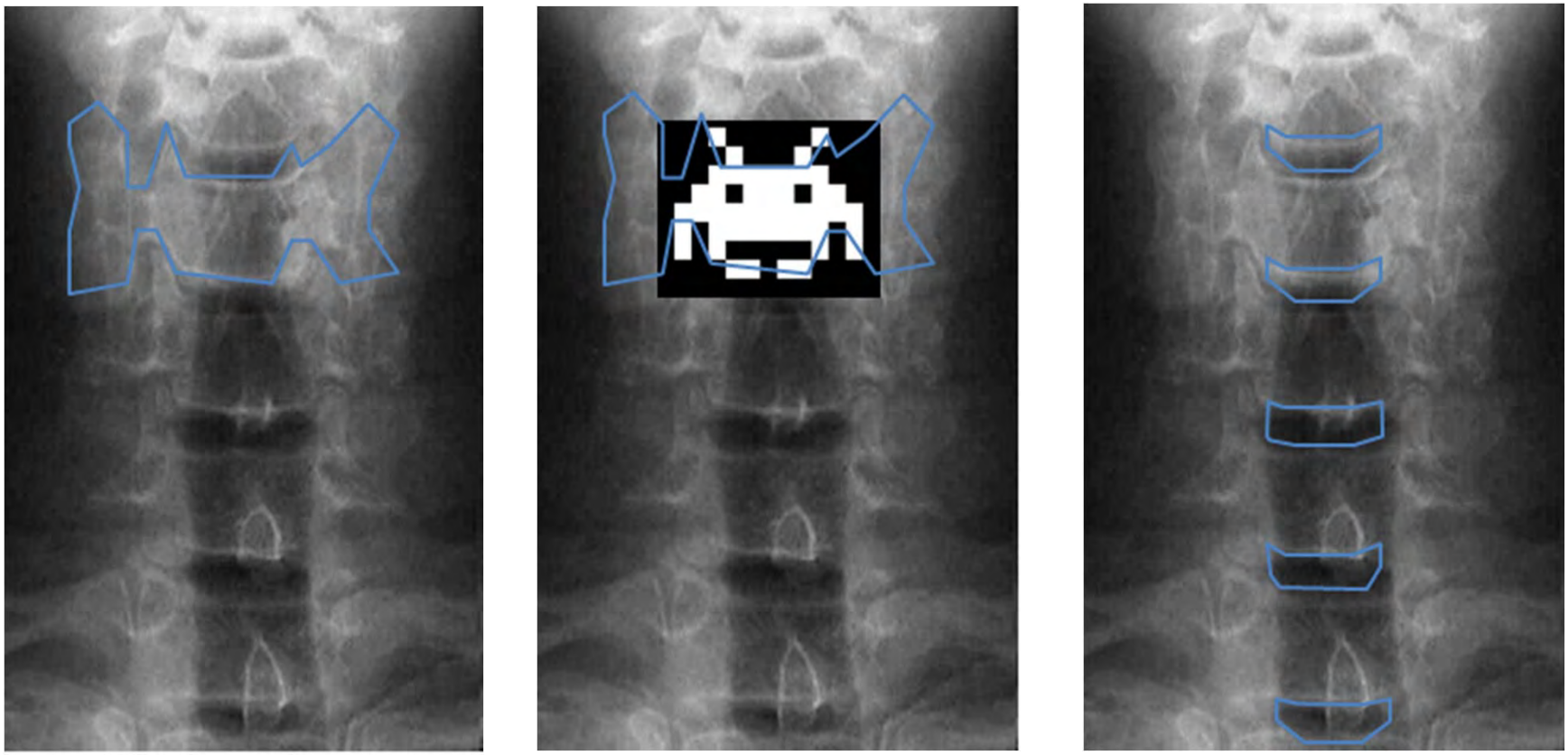

Odontoid View

- **Adequacy:**
  - Entire odontoid and the lateral borders of C1-C2 visable
- **Alignment:**
  - The tips of lateral mass of C1 should line up with the lateral margins of C2
  - The distance from the dens to the medial border of the lateral masses of C1 should be equal bilaterally
- **Bone:**
  - Look for any interrupted cortical margins

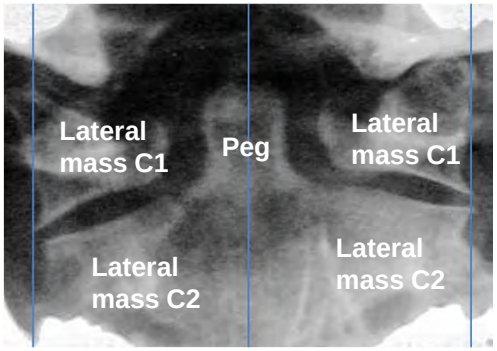

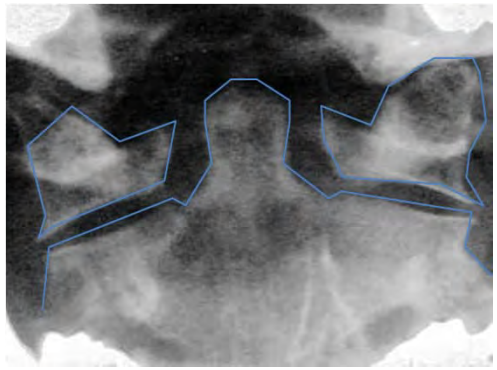

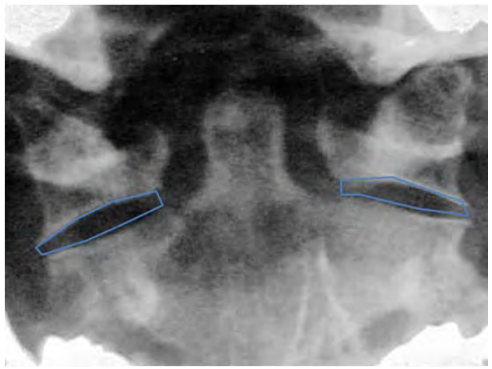

CT Basics

- Radiation considerations
- Orientation
- Views
- Windows
- Hounsfield Units

C-spine Fractures

Jefferson # (unstable)

- Compression # of C1 bony ring, characterized by lateral masses splitting and transverse ligament tear
- **Mechanism:** Axial blow to the head (eg. diving)
- **Radiographic features:** displacement of the lateral masses of C1 beyond margins of body of C2 (CT required)

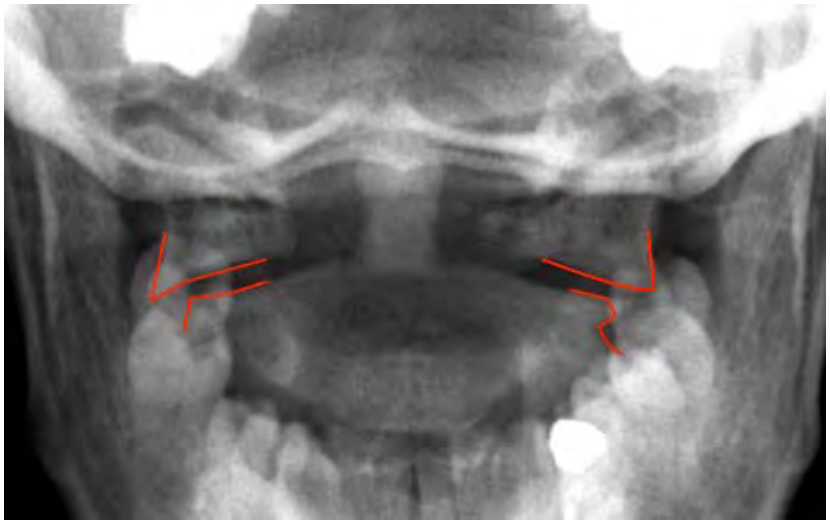

Hangman's # (unstable)

- Fracture through the pars interarticularis of C2 resulting from hyperextension and distraction

- **Mechanism:** hyperextension

- **Radiographic features:** (best seen on lateral view)
  - 1. Prevertebral soft tissue swelling
  - 2. Avulsion of anterior inferior corner of C2 (+ rupture of the anterior longitudinal ligament)
  - 3. Anterior dislocation of the C2 vertebral body
  - 4. Bilateral C2 pars interarticularis fractures

Hangman's # (2)

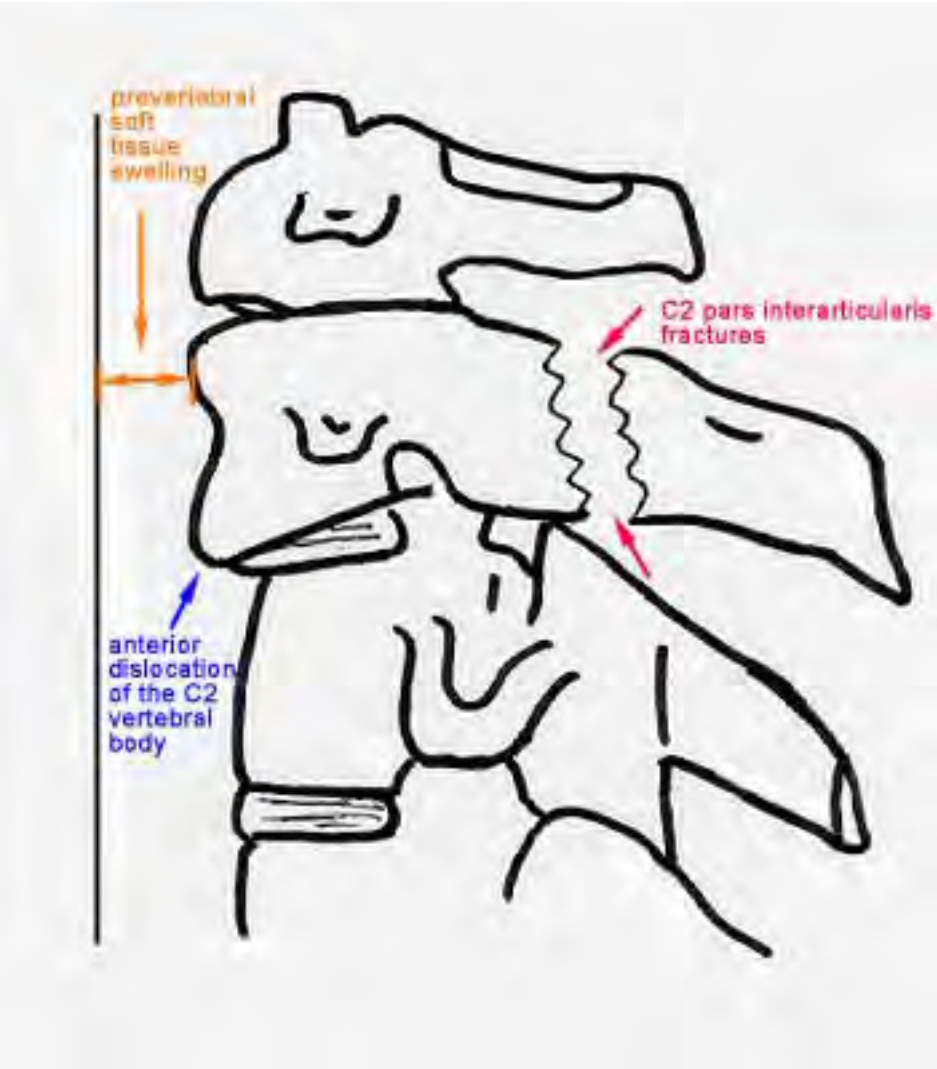
prevertebral
soft
tissue
swelling
C2 pars interarticularis
fractures
anterior
dislocation
of the C2
vertebral
body

Teardrop # (unstable)

- Post ligament disruption and ant compression # of VB from a severe flexion injury
- **Mechanism:** hyperflexion and compression (eg. diving into shallow water)
- **Radiographic features:** (best seen on lateral view)
  - 1. Prevertebral swelling (+ ant. longitudinal ligament disruption)
  - 2. Teardrop fragment (avulsion fracture) from anterior VB
  - 3. Posterior portion of VB displaced into the spinal canal
  - 4. Spinal cord compression
  - 5. Spinous process #

Teardrop # (2)

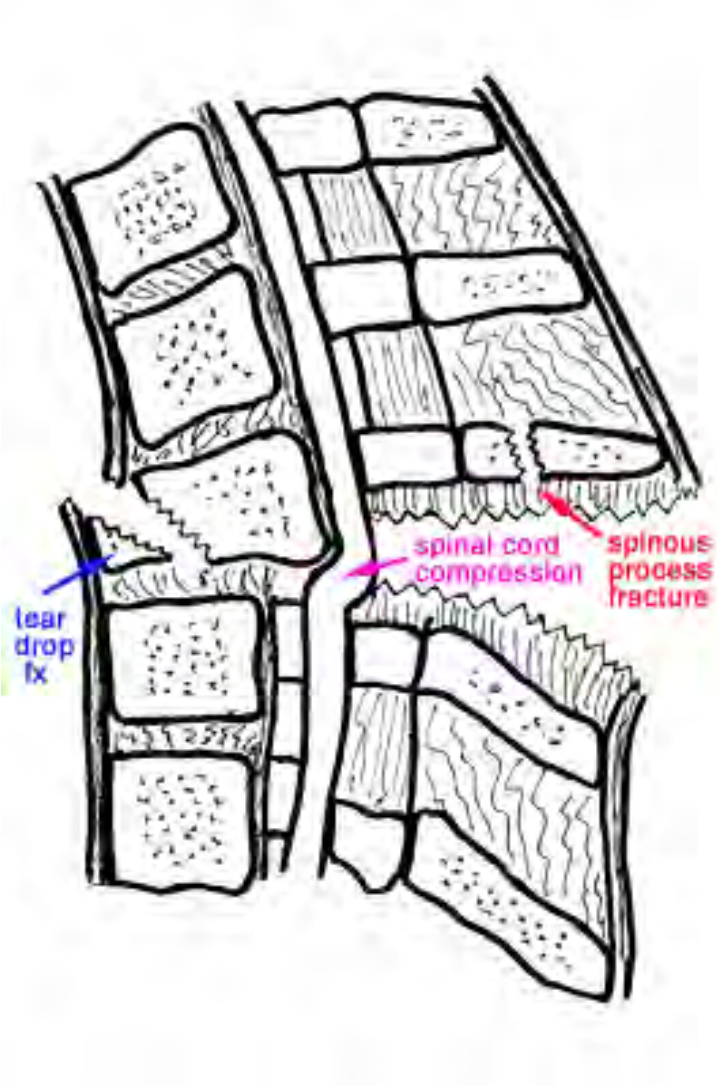
tear
drop
fx
spinal cord
compression
spinous
process
fracture


tear
drop
fx

Facet Joint Dislocation

Unilateral (stable)

- **Mechanism:** simultaneous flexion and rotation
- **Radiographic features:**
  - 1. Anterior dislocation of affected VB by ***< ½ of the vertebral body AP diameter***
  - 2. Facet within intervertebral foramen on oblique view
  - 3. Widened 'laminar' space
  - 4. "Bow tie" " appearance of the overriding locked facets

Bilateral (unstable)

- Complete anterior dislocation of the VB secondary to extreme hyperflexion
- ***High risk*** of cord damage
- **Mechanism:** extreme flexion of head and neck
- **Radiographic features:**
  - 1. Complete anterior dislocation of affected VB by ***½ or more of the vertebral body AP diameter***
  - 2. Disruption of the posterior and anterior ligaments
  - 3. Widened 'laminar' space
  - 4. "Bow tie" appearance of the locked facets

Unilateral Facet Joint Dislocation

- Bowtie appearance (white outline in image B)
- Widened laminar space

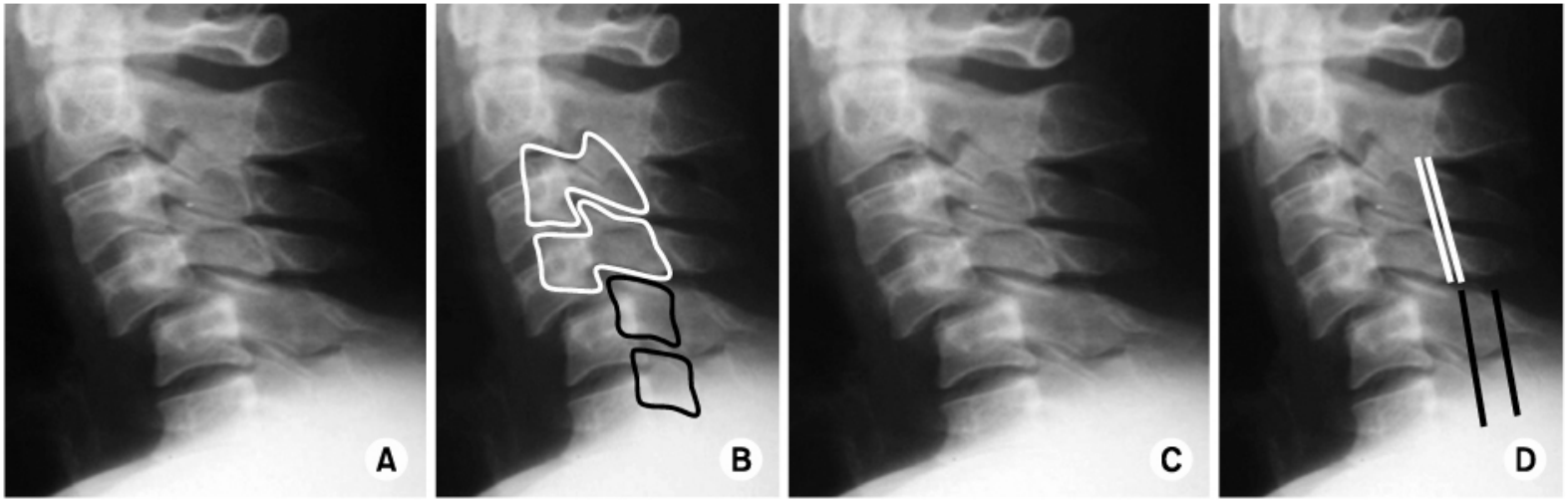

Bilateral Facet Joint Dislocation

- Anterior displacement of C5 > ½ width of the VB

Clay Shoveler's # (stable)

- Spinous process # C6-T1
- **Mechanism:** powerful hyperflexion combined with contraction of paraspinous muscles pulling on spinous processes (e.g. shoveling)
- **Radiographic features:**
  - 1. Spinous process # on lateral view

Wedge # (stable)

- Compression # resulting from flexion
- **Mechanism:** hyperflexion and compression
- **Radiographic features:**
  - 1. Buckled anterior cortex
  - 2. Loss of height of anterior VB
  - 3. Anterosuperior fracture of VB

Burst # (stable)

- C3-C7 # from axial loading
- Retropulsion of posterior fragments causing spinal cord compression
- Seen as double cortical line on lateral Xray with loss of posterior VB height
- CT all of these!

C-Spine Clearance in Comatose Patient

- CT C-spine
- CT not enough to exclude significant injury
- Options include:
  - Clinical assessment if likely to wake within 48 hours
  - MRI scan
  - Flexion-extension views under dynamic fluoroscopy
- Early consult with neurosurgery

Internet Images

- http://synapse.koreamed.org/DOIx.php?id=10.12671/jkfs.2011.24.1.100&vmode=PUBREADER
- http://radiopaedia.org/articles/clay-shoveler-fracture-2
- http://www.msdlatinamerica.com/ebooks/RadiologyReviewManual/sid401030.html
- http://www.med-ed.virginia.edu/courses/rad/cspine/index.html

Additional References

ACEM Diagnostic Imaging Guideline, Dec 2013

Available from:

https://www.acem.org.au/Standards-Publications/Policies-Guidelines.aspx

Hoffman JR, Mower WR, Wolfson AB, Todd KH, Zucker MI. Validity of a set of clinical criteria to rule out injury to the cervical spine in patients with blunt trauma. National Emergency X-Radiography Utilization Study Group. N Engl J Med. 2000 Jul 13;343(2):94-9.

Stiell IG, Clement CM, McKnight RD, Brison R, Schull MJ, Rowe BH, Worthington JR et al. The Canadian C-spine rule versus the NEXUS low-risk criteria in patients with trauma. N Engl J Med. 2003 Dec 25;349(26):2510-8.